




CLINICAL EVIDENCE FOLDER Endo-SPONGE®

ENDOLUMINAL VACUUM THERAPY FOR THE TREATMENT
OF RECTAL ANASTOMOTIC LEAKAGE



CONTENT

3 RATIONALE

6 CLINICAL EVIDENCE

14 KEY MESSAGES

16 ABSTRACTS

36 REFERENCES

RATIONALE

Anastomotic leakage is a major complication with an incidence of 10-13 % after anterior rectal resection¹. The frequency depends on various patient characteristics, the height of the anastomosis and the prior treatment in the case of a carcinoma. A rectal anastomotic leakage has the potential to lead to a high patient morbidity and mortality up to 22 %², because contents from the intestine can enter the minor pelvis via the anastomotic leakage and form an infected cavity. If the secretion continues to rise, generalized peritonitis can result, with severe septic progression involving multiple organ failure and potentially culminating in the death of the patient. In former times this complication has been treated conservative by transrectal rinsing if the patient shows no signs of a peritonitis, but this treatment method is associated with a very long postoperative period and healing time up to one year or more for the anastomotic leak. In addition, in some cases the creation of a permanent stoma is also necessary or the infection can not be controlled, leading to a reoperation of the patient with the necessity of a second stoma.

The vacuum drainage developed for wound therapy, represent an alternative treatment for anterior rectal anastomotic leaks. The principle of this method is the application of negative pressure on the wound surface with the help of a sponge connected to a pump. The physiological mechanism of this improvement in wound healing is the effective removal of fluid, tissue edema and bacteria, with subsequently improved local blood circulation, which in turn stimulates wound healing (increased growth of granulation tissue).

The endoluminal vacuum therapy as a minimally invasive method for the treatment of an anastomotic leakage after a low anterior rectum resection has been developed by the B. Braun together with Dr. Rolf Weidenhagen from the University hospital, Munic-Großhadern, Germany. The product "Endo-SPONGE" was introduced on the market in May 2006.

RATIONALE

Using the Endo-SPONGE treatment it is possible to achieve a continuous drainage of the secretion of the leakage cavity with simultaneous debridement, granulation of the surface and reduction of the size of the cavity. Endo-SPONGE consists of an open-pored sponge connected to a drainage tube. After endoscopic insertion of the sponge into the leakage cavity the drainage tube is routed out through the anus and connected to a vacuum system. The application of the vacuum leads to a continuous drainage of the fluid and the sponge in the cavity promotes the cleaning of the surface. To achieve an effective treatment the size of the sponge is cut to fit the cavity. Depending on the size of the leakage cavity it can be necessary to place more than one sponge into the cavity. The sponge system is changed every 24-72 hours. To change the sponge the vacuum is disconnected. Removal of the sponge is easier with prior irrigation with 0.9 % saline solution to remove the granulated tissue from the surface of the sponge. The sponge is removed through the anus and size of the new sponge is adapted to the size of the leakage cavity. Endo-SPONGE treatment is stopped as far as the cavity reaches a size of 1 x 0.5 cm, because no further reduction of the sponge size is technically possible.

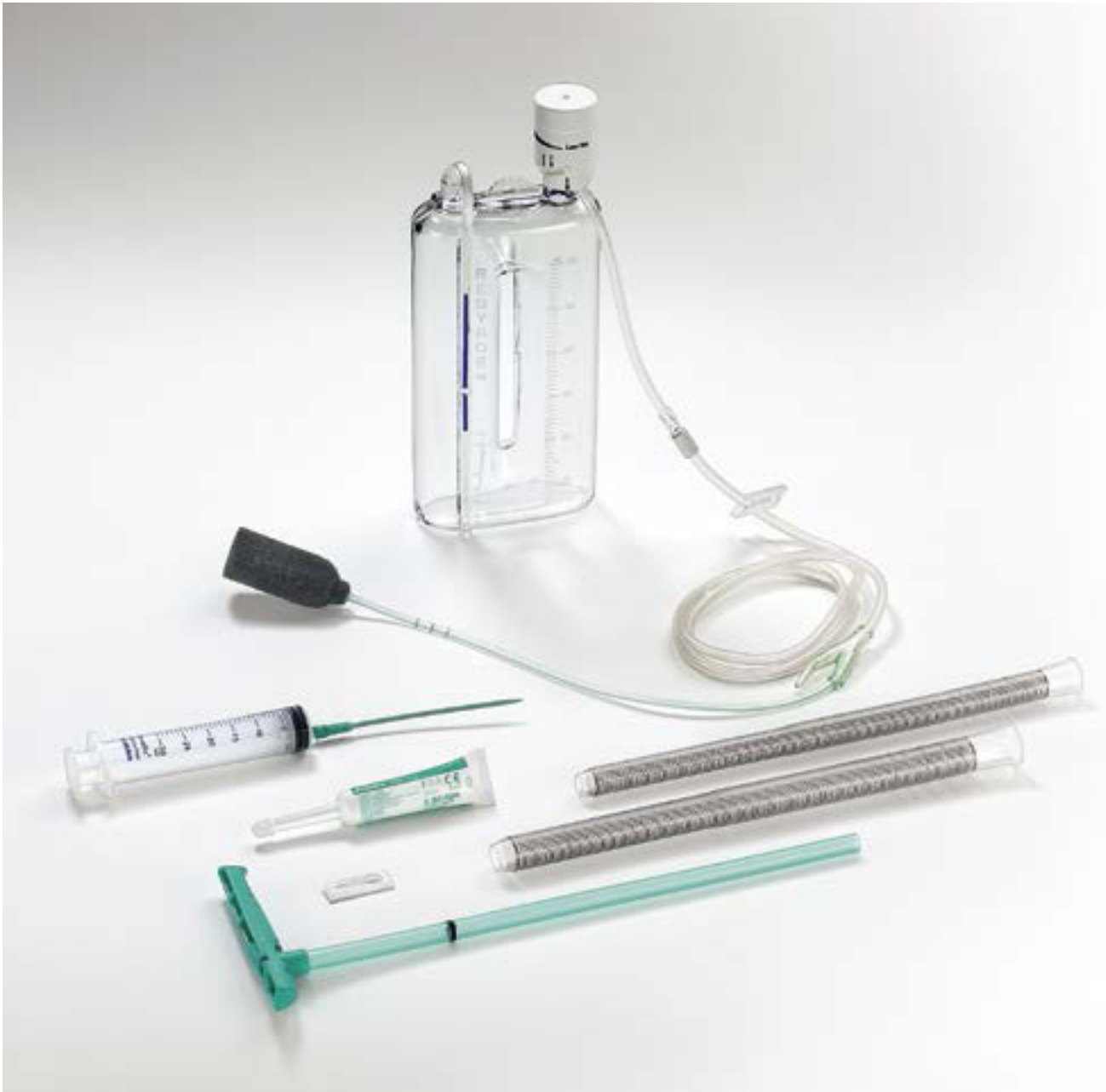

Figure 1: Endo-SPONGE treatment

CLINICAL EVIDENCE

ENDOLUMINAL VACUUM THERAPY FOR THE TREATMENT OF RECTAL ANASTOMOTIC LEAKAGE

COHORT STUDIES

The endoluminal vacuum therapy (EVT) for rectal anastomotic leakage treatment was firstly described by Weidenhagen in 2008³. Since then various retrospective and prospective cohort studies have been published using Endo-SPONGE to treat lower Gastrointestinal (GI) defects.

Up to present 40 publications including posters are available in Pubmed and EMBASE for Endo-SPONGE EVT and the outcome of these scientific investigations is summarized in the present clinical evidence folder.

Kuehn et al. performed in 2016 a retrospective patient series to analyse the result of EVT for lower GI defects⁴.

In total 41 patients were included between 2007 and 2015. Twenty patients were treated due to an anastomotic leakage after rectal resection, in 12 cases a Hartmann stump insufficiency was diagnosed, a rectal perforation was observed in 3 patients and in further 6 patients the EVT was applied due to other indications. In total 20 of 32 patients, whose suffered either of a rectal anastomotic leakage or a rectal stump insufficiency received preoperatively a radiotherapy- or a radio-chemotherapy. A protective enterostoma was created in 19 of 20 patients with a diagnosed rectal anastomotic leakage. The enterostoma could be closed in 15 of 19 patients (79 %). EVT was performed without using sedation or anesthesia. In all cases a vacuum of 125 mm Hg was applied and the sponges were changed every 3 days and adapted to the size of the cavity.

In total 426 sponges were applied during 360 endoscopic procedures. The median number of sponge insertions was 6 [1-37]. The median length of treatment duration was 23 days for anastomotic leakage, 12 days for rectal stump insufficiencies and 20 days for other GI defects. Depending on the gastrointestinal defect the success rate varied from 75 % to 90 %. In total 34/41 patients were successfully treated using Endo-SPONGE EVT. Mortality rate was 2.4 %.

The current cohort study is the largest patient series which has been published so far. The results showed that EVT is highly effective to treat various lower gastrointestinal defects. EVT has become the standard treatment within the University of Rostock, Department of General Thoracic, Vascular and Transplantation Surgery for anastomotic leakage after rectal resection.

The aim of the retrospective cohort study conducted by Keskin and colleagues was to describe the outcome of Endo-SPONGE EVT used for early and late treatment of anastomotic leakage after rectal surgery⁵.

Between 2009 and 2014 in total 15 patients undergoing Endo-SPONGE treatment for anastomotic leakage after proctectomy were enrolled in this case series. Lower anterior resection was performed in 12 patients, in 2 patients an operation due to a familial polyposis coli was done (total proctocolectomy) and one patient was operated because of a diverticular disease (total colectomy and ileorectal anastomosis). Endo-SPONGE was applied in 8 patients in early term and in 7 patients at late term. The sponges were cut to fit to the size of the cavity and changed every 3–4 days. Endo-SPONGE EVT was stopped as far as the granulation of the cavity has been developed.

Early term Endo-SPONGE treatment was started after an average period time of 15 days [min. 6 – max. 27 days] after surgery; in the late term treatment group after 173 days [min. 43 – max. 342 days]. The average number of used sponges was 2.2 [1–5]. Cavity closed successfully in 12 patients (80 %). In 3 patients the Endo-SPONGE treatment was terminated because in one case a bleeding in the cavity was seen and in the other 2 cases the progression of the pelvic sepsis was observed. A stoma was created in 14 patients. After Endo-SPONGE treatment stomas were closed in 10 of 14 patients. No abscess recurrence was seen. Complication rate in early treated patients was 75 % and 85 % in the late treated patients. Three patients died due to a systematic disease.

Authors concluded that Endo-SPONGE can shorten the time required to close a diverting stoma. Endo-SPONGE treatment is effective at addressing this colorectal problem and it is sufficient to use Endo-SPONGE until tissue granulation develops in the cavity.

Strangio et al. aimed to assess the efficacy and safety of Endo-SPONGE treatment in a large cohort and they also performed a review of the literature⁶.

Consecutive patients (N = 25) with an anastomotic leakage after a colorectal surgery with or without the need of a protective stoma were included in this retrospective cohort study. A protective stoma was performed in 13 patients (52 %). The size of the circumference leading to an anastomotic leakage ranged from 70 to 270 degrees. The detection of the anastomotic leakage took place after a median of 17 days after surgery. The Endo-SPONGE treatment started after a median of 16 days after detection. The sponges were changed every 48–72 hours. A median number of 9 sponges were applied per patient [min. 1 – max. 39]. The treatment was stopped when the cavity was less than 1 cm in diameter. Healing of the cavity was observed after a median duration of 28 days [min. 7 – max. 128 days]. Success rate of Endo-SPONGE treatment was 88 % (22/25 patients). In total 3 patients developed a major complication (ureteric fistula, ileal fistula, pararectal abscess). Ureteric fistula was surgical treated with the placement of an uterine J stent and antibiotic therapy. The ileal fistula was managed with a second laparotomy with bowel segmental resection and anastomotic leak repair. The patient with the pararectal abscess received a CT guided transgluteal drainage, antibiotic therapy and hyperbaric oxygen therapy but only a partial improvement could be observed. Mortality rate was 12 % (3/25 patients). The patients died due to tumor progression, but in none of these cases a possible relationship with Endo-SPONGE was recorded. Closure of the stoma could be performed in 11 of 13 patients (84.6 %).

During their literature research the authors could identify 12 publications using Endo-SPONGE for colorectal anastomotic leakage. In total 174 patients were recorded ranging from 1 to 29 patient per cohort study. Subanalysis of the 7 largest case series including in total 149 patients showed a complete healing rate of the cavity in 94.3 %, over a treatment duration of 34 days with a median application of 11 sponges and a closure rate of the stoma from 55–92 %. A complication rate of 20 % was reported mainly including abscess recurrence, fistula and anastomosis stenosis.

Authors confirm the safety and efficacy of Endo-SPONGE treatment for colorectal anastomotic leakage with a low complication rate.

CLINICAL EVIDENCE

Gardenbroek et al. evaluated the effectiveness and direct costs of Endo-SPONGE to treat anastomotic leakage after ileal pouch-anal anastomosis (IPAA) construction in comparison to conventional treatment⁷.

The current study was prospectively performed. In 15 patients Endo-SPONGE was early applied to manage the anastomotic leakage in a short term course, thereafter the defect was closed surgically. As a retrospective control group 29 patients were used, whose were treated conventionally. The conventional treatment consists of the creation of a diverted ileostomy and depending on the size of the cavity, in addition a transanal or percutaneous drainage of the abscess was performed. After confirmation of the healing of the cavity stoma was closed. The main outcome of this cohort study was the percentage of secondary healed anastomosis until 6 months, without the presence of an anastomotic defect or abscess. Costs were calculated for both treatments including the costs from the diagnosis of the anastomotic leakages until the closure of the stoma or until 2 years if a stoma closure could not yet be performed.

In total 14 of 15 patients received a protective stoma in the Endo-SPONGE treated group. The VAC therapy was started after a median of 2 days after diagnosis of the anastomotic leakage. Patients were treated for a median duration of 12 days with 3 sponge changes. The surgically closure treatment of the anastomotic defect was performed after a median of 15 days. In 2 patients the surgical closure was not successful therefore, a second round of VAC treatment was initiated. The following surgically closure lead to success. Anastomotic healing rate was 100 % in the Endo-SPONGE group and 52 % in the conventional treatment group; $p = 0.003$. Healing was achieved in the Endo-SPONGE group after 48 days, whereas 70 days were necessary in the conventional treated group; $p = 0.013$. At the end of the follow-up a functional pouch was observed in 24 of 28 conventional treated patients and in 14 of 15 patients receiving Endo-SPONGE therapy. Costs for the Endo-SPONGE treatment were calculated at 27.627 € per patient and 33.441 € for a conventionally treated patient; $p = 0.529$.

In conclusion, this study demonstrated that Endo-SPONGE treatment is a highly effective method to treat anastomotic leakages after IPAA by avoiding permanent stoma without an increase of direct medical costs.

Aim of the retrospective study performed by Nerup et al. was to evaluate the VAC therapy for anastomotic leaks after low anterior resection of rectal cancer⁸.

Endoscopic vacuum therapy using Endo-SPONGE was applied in 13 patients receiving a protective temporary ileostomy for 3 months. Sponges were changed every 2-3 days and the sponges were trimmed to the size of the cavity. The endoscopic vacuum treatment was stopped as far as the cavity was covered by granulated tissue and possessed a width of 3 cm. A median hospital stay of 25 days [7-39 days] was reported. All abscess cavities could successfully treated. Per patient a median number of 8 sponges were applied. A median duration of 18 days was recorded for Endo-SPONGE treatment and no patient deceased. Only one complication was recorded. In one patient a stenosis occurred which was managed by a reoperation and a permanent colostomy. No recurrent abscess was observed in the study population. Closure rate of the protective stoma was 92 % (12/13 patients).

The endoscopic vacuum therapy using Endo-SPONGE is safe to treat lower GIT defects. Endoscopic VAC therapy shortens the duration of the treatment period in comparison to conservative irrigation.

Srinivasamurthy et al. reported their initial experience using minimal invasive Endo-SPONGE treatment in patients with low pelvic anastomotic leakage⁹.

Eight patients were included in this case series suffering from leaks after low anterior resection for rectal cancer. All patients had a protective ileostomy at the initial surgery. Radical radiotherapy was performed previously in 7 patients due to a carcinoma of the bladder and 6 patients underwent preoperatively a short course of radiotherapy due to the rectal cancer. Endo-SPONGE treatment was performed according to the instruction of use. The anastomotic leaks were detected postoperatively after a median time of 29 days. In most of the cases 4 sponges were needed for endoscopic VAC therapy during a median treatment duration of 26 days. The pre-sacral abscess completely healed or was reduced in 6 of 8 patients. A stoma closure rate of 62.5 % was reported. Two patients were managed with a permanent stoma and in one case an abdomino-perineal excision of the rectum was done due to persisting perineal sepsis.

Authors summarized that the minimal invasive endoscopic vacuum therapy using Endo-SPONGE is a highly effective and a well tolerated approach to treat and to close presacral cavities after pelvic anastomotic leakage. Furthermore, this treatment reduces the risk for a permanent stoma and results in an acceptable bowel function.

Riss et al. designed a multicentric study to analyse the long term efficacy of Endo-SPONGE treatment for lower GIT defects¹⁰.

In six centers 20 consecutive patients were enrolled whose underwent rectal cancer surgery. Endo-SPONGE treatment was performed in 17 of 20 patients due to an anastomosis leakage and in 3 patients because an insufficiency of the Hartmann stump was diagnosed. The median time from the primary surgery until the diagnosis of the anastomotic leakages was 12.5 days. One patient received neoadjuvant short-term radiotherapy, in 5 patients a long term chemo/radiotherapy was indicated before rectal surgery. Patients were followed up for 17 months [1.5 – 29.8 months]. Five patients died, four due to tumor progression and one patient because of a liver failure. Median duration for Endo-SPONGE treat-

ment was 21 days [7-106 days]. During Endo-SPONGE treatment 9 patients had a protective ileostomy and 8 patients a colostomy. In 13 patients (76.5 %) the stoma was closed after successful Endo-SPONGE treatment. The overall success rate of Endo-SPONGE treatment was 75 % (15/20 patients). In five patients a recurrent abscess was observed. Median time between last Endo-SPONGE treatment and occurrence of the abscess was 255 days [21-733 days].

Authors showed that after primary successful Endo-SPONGE treatment, 25 % of the patients developed a recurrent abscess. Therefore, patients should be monitored very closely within the first 2 years, because abscess recurrence might be occurred.

Van Koperen et al. aimed to evaluate the effectiveness of Endo-SPONGE treatment for anastomotic leakage after colorectal cancer surgery¹¹.

After reviewing the patient's charts between July 2006 and April 2008, in total 16 patients could be identified whose were eligible for this retrospective cohort analysis. Thirteen patients were operated due to a rectal cancer and 3 patients underwent ulcerative colitis. In 9 of 13 patients scheduled for a colorectal resection a radiotherapy was preoperatively performed and in 2 patients a chemoradiotherapy was done. A protective stoma was created in 8 patients. The anastomotic leakage was observed after a median duration after surgery of 11 days [3-150 days]. Half of the patients were treated with Endo-SPONGE within 6 weeks after surgery and the sponges were placed after a median time of 24 days [13-39 days]. Treatment of the remaining patients started at a median period of 74 days [43-1.602 days]. In 16 patients a median number of 13 [8-17] sponge changes were reported. Median healing time of the cavity was 40 days [28-90 days]. Closure of the abscess cavity was seen in 56 % (9/16 patients).

Authors conclude that Endo-SPONGE is a promising device and could potentially be helpful in the treatment of anastomotic leakage after colorectal surgery and may prevent the development of a chronic presacral sinus. Early treatment with Endo-SPONGE is probably more effective than the late treatment of the abscess cavity.

CLINICAL EVIDENCE

The first assessment of the safety and efficacy of Endo-SPONGE was performed by Weidenhagen et al. in 2008³.

In this cohort study endoscopic vacuum therapy using Endo-SPONGE was applied in 29 patients to manage anastomotic leakages followed by anterior rectum resections. Primary surgery was performed due to rectal carcinoma (N = 22), rectosigmoidal cancer (N = 3), a large rectal adenoma (N = 2), a diverticulitis (N = 1) and a rectal infiltration of endometrial cancer (N = 1). In total 9 of 29 patients received a radiochemotherapy preoperatively. A protective stoma was created in 25 patients. The anastomotic leakage was diagnosed 8.2 ± 3.6 days postoperatively. Patients were treated for a median duration of 34 days [4–79 days] using a median number of 11 [1–27] sponges. Granulation of the tissue was seen after initial treatment in all cases. Healing rate of the abscess cavity was 96.5 % (28/29 patients). Protective stoma could be closed in 22 of 25 patients. Postoperative stay varied between 10 and 69 days.

Weidenhagen et al. summarized that the endoscopic vacuum treatment is a safe and efficient minimal invasive option to drain an abscess occurring after anterior rectal resections. Further studies are needed to demonstrate that this treatment have the potential to reduce the high mortality rate of patients suffering from this disease and to preserve at the same time the sphincter function.

Table 1: Publications using Endo-SPONGE for rectal anastomotic leakage treatment

Author	Year	Number of patients	Age of the patients (years) [min. – max.]	Number of sponges [min. – max.]	Median treatment duration (days) [min. – max.]	Success rate	Stoma closure	Mortality rate
Kuehn et al. ⁴	2016	N = 41	70 [29-91]	6 [1-37]	20 days [2-131]	34/41 82.3 %	15/19 78.9 %	1/41 2.4 %
Keskin et al. ⁵	2015	N = 15	55 (25-72)	2 [1-5]	NA	12/15 80 %	10/14 71.4 %	3/15 20 %
Strangio et al. ⁶	2015	N = 25	67 [37-89]	9 [1-39]	28 days [7-128]	22/25 88 %	11/13 84.6 %	3/25 12 %
Gardenbroek et al. ⁷	2015	N = 15	37 [25-56]	3 [2-4]	12 [7-15]	15/15 100 %	14/15 93.3 %	0/15 0 %
Nerup et al. ⁸	2013	N = 13	64 [36-71]	8 [1-18]	18 [3-40]	13/13 100 %	12/13 92.3 %	0/13 0 %
Srinivasamurthy et al. ⁹	2013	N = 8	66 [45-79]	4 [1-7]	26 [7-49]	6/8 75 %	5/8 62.5 %	0/8 0 %
Verlaan et al. ¹²	2011	N = 6	52 [29-68]	3 [1-6]	14 [5-28]	6/6 100 %	5/6 83.3 %	0/8 0 %
Arezzo et al. ¹³	2010	N = 3	69 [62-73]	2 [1-4]	21 [NA]	1/3 33.3 %	2/3 75 %	0/3 0 %
Riss et al. ¹⁰	2010	N = 20	66 [55-91]	NA	21 [7-106]	15/20 75 %	13/17 76.5 %	5/20 25 %
Riss et al. ¹⁴	2010	N = 9	63.5 [50-71]	NA	21 [14-56]	6/9 66.6 %	NA	1/9 11.1 %
Heeney et al. ¹⁷	2010	N = 2	68.5 [58-79]	NA	21 [NA]	2/2 100 %	NA	0 0 %
van Koperen et al. ¹¹	2009	N = 16	64 [19-78]	13 [8-17]	40 [28-90]	9/16 56 %	5/8 62.5 %	0/16 0 %
Weidenhagen et al. ³	2008	N = 29	66.7 [42-79]	11 [1-27]	34 [4-79]	28/29 97 %	22/25 88 %	0/29 0 %
Richterich et al. ¹⁵	2008	N = 1	60	NA	9	1/1 100 %	NA	0 0 %
van Koperen et al. ¹⁶	2008	N = 2	29 [18-40]	NA	45.5 [35-56]	2/2 100 %	NA	0 0 %

Legend: NA: Not applied

CLINICAL EVIDENCE

POSTER/ABSTRACTS

Several posters were presented by different surgeons on various congresses. The outcome of rectal anastomotic leakage treatment is demonstrated in table 2. The content of the posters are shown in the abstract chapter of this clinical evidence folder.

CONCLUSION

Since its introduction into the market in 2006, numerous clinical investigations including over 290 patients have been performed using Endo-SPONGE to treat anastomotic leakages occurring after anterior rectal cancer resection. The authors assessed the endoscopic vacuum treatment using Endo-SPONGE as a safe and high efficient minimal invasive option. This approach is well tolerated by the patient and associated with a low complication rate. The Endo-VAC treatment reduces the high mortality rate of the patients, prevents the development of a chronic presacral sinus and minimises the risk of a permanent stoma. After diagnosis of the anastomotic leak the endoscopic vacuum treatment should be started immediately because early treatment is more effective as late treatment of the abscess cavity. Chemo-radiotherapy delays the closure of the abscess. In comparison to conservative irrigation, Endo-SPONGE treatment shortens the treatment period and patients return quicker to normal life and work. The endoscopic vacuum therapy using Endo-SPONGE reduces the costs for the patient medical treatment and for the society. A success rate between 56 % and 100 % has been reported in the literature for this minimal approach.

Table 2: Posters using Endo-SPONGE to treat rectal anastomotic leakage

Author	Year	Number of patients	Age of the patients (years) [min. – max.]	Mean number of sponges [min. – max.]	Median treatment duration (days) [min. – max.]	Success rate	Stoma closure	Mortality rate
Milito et al. ^{18,19}	2013	N = 12	NA	11.5 [8-15]	35 [16-51]	12/12 100 %	NA	0/12 0 %
Mc Auley et al. ²⁰	2013	N = 3	NA	9 [7-12]	NA	3/3 100 %	NA	0/3 0 %
Repici et al. ²¹	2013	N = 22	67 [37-89]	NA	28 [7-224]	18/22 82 %	NA	3/22 13.6 %
Martel et al. ²²	2013	N = 10	59	7 [2-11]	28.5 [8-40]	4/10 40 %	NA	0/10 0 %
Milito et al. ²³	2012	N = 8	NA	8-15	27	8/8 100 %	NA	0/8 0 %
Buzzi et al. ²⁴	2012	N = 9	NA	15 [9-23]	NA	8/9 88.8 %	8/9 88.8 %	0/9 0 %
Cadeddu et al. ²⁵	2011	N = 8	NA	11.5 [8-15]	27	8/8 100 %	NA	0/8 0 %
Cadeddu et al. ^{26,27}	2011	N = 5	66 [42-75]	11.5 [8-15]	25 [16-35]	5/5 (100 %)	NA	0/5 0 %
Marino et al. ²⁸	2011	N = 1	62	15	NA	1/1 100 %	NA	0/1 0 %
Milito et al. ²⁹	2010	N = 5	NA	8-15	25	5/5 (100 %)	NA	0/5 0 %
Morino et al. ³⁰	2010	N = 2	NA	12-17	35-45	2/2 100 %	NA	0/2 0 %
Di Mitri et al. ³¹	2010	N = 5	51.6 [32-67]	6 [1-15]	30 [20-50]	5/5 100 %	5/5 100 %	0/5 0 %

Legend: NA: Not applied

KEY MESSAGES

- Endo-SPONGE treatment is a safe and high efficient approach to treat anastomotic leaks occurring after anterior rectal cancer resection^{3-8,11}.
- Endo-SPONGE is well tolerated by the patient^{9,14,15,32}.
- Endo-SPONGE treatment is associated with a low complication rate^{6,33}.
- Endo-SPONGE endoscopic vacuum treatment reduces the mortality rate of the patients suffering of an abscess cavity after rectal resection (table 1, 2).
- The Endo-VAC treatment prevents the development of a chronic presacral sinus and minimises the risk of a permanent stoma^{3,34}.
- Endo VAC treatment using Endo-SPONGE shortens the treatment period in comparison to conservative irrigation^{8,11}.
- Endo-SPONGE treatment leads to a quicker return to normal life and work³.
- The use of Endo-SPONGE reduces the costs for patient's medical treatment and the society^{3,35}. Endo-VAC treatment avoids complicated, time- and cost consuming open surgical reoperations. Also the total cost of treatment can be reduced in endoscopically treated patients by reducing the time of total parental nutrition, systemic antibiotics and intensive care³⁵.
- Success rate of Endo-SPONGE treatment ranges between 56-100 % (table 1, 2).
- The earlier the Endo VAC treatment is initiated after leak diagnosis the better the outcome and the lower the complication rate^{11,34}.
- Transanal Endo VAC may be a first line treatment for patients with major leaks after rectal anastomoses. This therapy is effective in patients following neoadjuvant chemoradiotherapy^{33,35}.

J Gastrointest Surg. 2016 Feb;20(2):237–43.

Surgical Endoscopic Vacuum Therapy for Defects of the Upper Gastrointestinal Tract.

Kuehn F¹, Schiffmann L^{2,3}, Janisch F², Schwandner F², Alsfasser G², Gock M², Klar E².

Author information:

- 1 Department of General, Thoracic, Vascular and Transplantation Surgery, University of Rostock, Schillingallee 35, 18057, Rostock, Germany. florian.kuehn@med.uni-rostock.de.
- 2 Department of General, Thoracic, Vascular and Transplantation Surgery, University of Rostock, Schillingallee 35, 18057, Rostock, Germany.
- 3 Protestant Hospital Lippstadt, Wiedenbrücker Str. 33, 59555, Lippstadt, Germany.

INTRODUCTION: Endoscopic vacuum therapy (EVT) has been established in Germany for the treatment of anastomotic leakage after rectal resection. Continuous or intermittent suction and drainage decrease bacterial contamination, secretion, and local edema promoting perfusion and granulation at the same time. However, data for use and long-term results of EVT in colorectal surgery are still scarce and are often limited by short-term follow-up.

OBJECTIVES: Here, we aimed at analyzing the treatment spectrum and long-term outcome of EVT for defects of the lower gastrointestinal tract.

METHODS: This is a retrospective single-center analysis of EVT for defects of the lower gastrointestinal tract of different etiology in 41 patients over a time period of 8 years (2007–2015) with a mean follow-up of 36 (2–89) months.

RESULTS: In total, 426 polyurethane sponges were placed in lower GI defects of 41 patients (31 male, 10 female) with a median age of 70 years (range, 29–91). Most frequent indications for EVT were anastomotic leakage after rectal resection (N = 20), Hartmann's stump insufficiency (N = 12), and rectal perforation (N = 3). The median number of sponge insertions was six (range, 1–37) with a mean changing interval of 3 days (range, 1–5). Median time of therapy was 20 days. A successful vacuum therapy with local control of the septic focus was achieved in 18 of 20 patients (90 %) with anastomotic leakage after rectal resection and in nine of 12 patients with a Hartmann's stump insufficiency. In 15 of 19 (79 %) patients with a diverting stoma, take-down after successful treatment was possible. Median time to closure was 244 days (range, 152–488 days).

CONCLUSION: To our knowledge, this retrospective observation of EVT application for rectal lesions represents the largest patient series in literature. EVT has earned its indication in complication management after colorectal surgery and can achieve a successful control of a local septic focus in the majority of patients.

Surg Laparosc Endosc Percutan Tech. 2015 Dec;25(6):505-8.

Effectiveness of Endoluminal Vacuum-assisted Closure Therapy (Endo-SPONGE) for the Treatment of Pelvic Anastomotic Leakage After Colorectal Surgery.

Keskin M¹, Bayram O, Bulut T, Balik E.

Author information:

1 *Department of General Surgery, Istanbul University, School of Medicine

+Department of General Surgery, Koc University School of Medicine, Istanbul, Turkey.

Anastomotic leakage is a serious complication with significant morbidity and mortality. The popularity of endoscopic treatment (Endo-SPONGE) is increasing for distally located colorectal pouch-anal anastomotic leakages. This was a retrospective study of 15 cases involving the application of the Endo-SPONGE for anastomotic leakage following proctectomy between May 2009 and May 2014. Of the 15 cases, lower anterior resection occurred in 12 cases (80 %), and pouch-anal anastomosis in 3 cases (18 %). In 8 patients (55 %), the Endo-SPONGE was applied during the early term, and in 7 patients (45 %) during the late term. The average number of applications was 2.2 (range, 1 to 5). Treatment was discontinued due to the progression of pelvic sepsis in 2 patients and due to bleeding in 1 patient. Lumen integrity was achieved in 12 cases. Lumen integrity after anastomotic leakages can be preserved by endoluminal vacuum therapy, which permits the closure of the stoma without requiring reconstructive surgery.

ABSTRACTS

Dig Liver Dis. 2015 Jun;**47(6):465-9.**

Endo-SPONGE therapy for management of anastomotic leakages after colorectal surgery: A case series and review of literature.

Strangio G¹, Zullo A², Ferrara EC¹, Anderloni A¹, Carlino A¹, Jovani M¹, Ciscato C¹, Hassan C³, Repici A¹.

Author information:

- 1 Department of Gastroenterology, IRCCS Istituto Clinico Humanitas, Milan, Italy.
- 2 Gastroenterology and Digestive Endoscopy, 'Nuovo Regina Margherita' Hospital, Rome, Italy. Electronic address: angelozullo66@yahoo.it.
- 3 Gastroenterology and Digestive Endoscopy, 'Nuovo Regina Margherita' Hospital, Rome, Italy.

BACKGROUND: Endo-SPONGE treatment is a novel approach to manage selected patients with anastomotic leakage following colorectal surgery. However, the available data are still scanty.

AIMS: To evaluate the efficacy and safety of the Endo-SPONGE therapy in a large series, and to perform a review of the current evidence concerning such a treatment.

METHODS: Consecutive patients diagnosed with partial colonic anastomotic leakage managed with Endo-SPONGE placement were enrolled. The Endo-SPONGE system was changed every 48-72 h as outpatient, until to cavity closure. Literature review was performed for pooled-data analysis.

RESULTS: Twenty-five patients were enrolled, including 13 (52 %) with diverting ileostomy. Following Endo-SPONGE applications (median sessions: 9, range: 1-39; median treatment duration: 4 weeks, range: 1-32), a complete healing was achieved in 22 (88 %) patients. Three (12 %) patients developed a major complication (1 urethric fistula, 1 ileal fistula, and 1 pararectal abscess), all successfully treated by surgery. Ileostomy closure was achieved in 11 (84.6 %) patients. No mortality related to the procedure was observed. Overall, 174 patients treated with Endo-SPONGE were reported in literature. By considering data of the larger 7 studies, a complete healing of presacral cavity was achieved in 131 (94.3 %) out of 149 patients.

CONCLUSIONS: Our relatively large series of patients confirmed the efficacy, tolerability, and an acceptably low complication rate of Endo-SPONGE therapy for colorectal anastomosis leakage treatment.

Colorectal Dis. 2015 May;17(5):426–32.

Early reconstruction of the leaking ileal pouch–anal anastomosis: a novel solution to an old problem.

Gardenbroek TJ¹, Musters GD, Buskens CJ, Ponsioen CY, D'Haens GR, Dijkgraaf MG, Tanis PJ, Bemelman WA.

Author information:

1 Department of Surgery, Academic Medical Centre, Amsterdam, The Netherlands; Department of Surgery, Onze Lieve Vrouwe Gasthuis, Amsterdam, The Netherlands.

AIM: The study aimed to determine the effectiveness and direct medical costs of early surgical closure of the anastomotic defect after a short course of Endo-SPONGE therapy of the presacral cavity, compared with conventional treatment in patients with anastomotic leakage after ileal pouch–anal anastomosis (IPAA).

METHOD: Patients with anastomotic leakage after IPAA undergoing early surgical closure of the anastomotic defect after a short Endo-SPONGE treatment were prospectively followed and compared with a consecutive cohort of patients with an anastomotic leak treated by creation of a loop ileostomy and occasional drainage of the presacral cavity.

RESULTS: A total of 15 patients were treated with early surgical closure and 29 were treated conventionally. In the early surgical closure group, the Endo-SPONGE treatment was continued for a median of 12 days [interquartile range (IQR) 7–15 days] with a median of 3 (IQR 2–4) Endo-SPONGE changes. Secondary anastomotic healing was achieved in all patients (N = 15) in the early surgical closure group compared with 52 % (N = 16) in the conventional treatment group (p = 0.003). Closure of the anastomotic defect was achieved after a median of 48 (25–103) days in the early surgical closure group compared with 70 (IQR 49–175) days in the conventional treatment group (p = 0.013). A functional pouch was seen in 93 % and 86 % of the patients in each group. There was no significant difference in direct medical cost.

CONCLUSION: Early surgical closure after a short period of Endo-SPONGE treatment is highly effective in treating anastomotic leakage after IPAA without increasing cost.

Dan Med J. 2013 Apr;60(4):A4604.

Promising results after endoscopic vacuum treatment of anastomotic leakage following resection of rectal cancer with ileostomy.

Nerup N, Johansen JL, Alkhefagie GA, Maina P, Jensen KH.

Author information:

1 Department of Surgical Gastroenterology, Hvidovre Hospital, 2650 Hvidovre, Denmark. nikolajnerup@gmail.com

INTRODUCTION: In colorectal surgery, the most feared complication is anastomotic leakage (AL), which is associated with a high morbidity and mortality. In this study, we focus on treatment of perianastomotic abscess following AL after low anterior resection (LAR) of rectal cancer. In the literature, conservative irrigation regimes are reported to perdure for months and some even years and to be associated with a poor stoma closure rate. In the present paper, we evaluated endoscopic vacuum treatment of the perianastomotic abscess.

MATERIAL AND METHODS: Patients who had LAR due to rectal cancer with total mesorectal excision (TME) performed in Slagelse and Næstved Hospitals in the 2008–2012 (1st February) period were identified in the Danish Colorectal Cancer Group database. We included patients who had AL and who did not require emergency reoperation and were treated with endoscopic vacuum in the study period. Patients who initiated treatment more than one month after the leakage were excluded. All patients had primary ileostomy.

RESULTS: A total of 13 patients were included. All patients had successful closure of the perianastomotic abscess for a median of 18 (3–40) days in a median of eight (1–18) sessions. The median length of hospital stay was 25 (7–39) days. Mortality was zero, and the stoma closure rate was 12/13 (97 %).

CONCLUSION: Our data support the positive findings previously reported by other studies. Endoscopic vacuum treatment seems to be a safe approach for selected patients in the treatment of perianastomotic abscess after LAR with TME of rectal cancer.

ABSTRACTS

Tech Coloproctol. 2013 Jun;17(3):275-81.

An initial experience using transanal vacuum therapy in pelvic anastomotic leakage.

Srinivasamurthy D, Wood C, Slater R, Garner J.

Author information:

1 Department of Colorectal Surgery, The Rotherham NHS Foundation Trust, Moorgate Road, Rotherham, South Yorkshire, S60 2UD, UK.

BACKGROUND: Treatment of the presacral cavity that forms after contained anastomotic leakage of a low pelvic anastomosis is challenging and often results in a permanent stoma. Endo-SPONGE therapy is a minimally invasive method of treating the presacral cavity which potentially avoids a permanent stoma. We report our initial experience of using Endo-SPONGE therapy.

METHODS: All patients who underwent Endo-SPONGE treatment for low pelvic anastomotic leakage in our hospital over a 45-month period were identified and data collected from clinical, operative and endoscopic notes.

RESULTS: Eight patients (seven males, one female) underwent Endo-SPONGE therapy for extraperitoneal pelvic anastomotic leak during the study period; all had had defunctioning ileostomies placed at their original surgery. Six out of eight patients had complete closure or a reduction in the size of the abscess cavity. Five patients have had their ileostomies reversed with good or reasonable bowel function after a median follow-up of 41 months and four of these patients had Endo-SPONGE therapy instituted within 6 weeks of initial surgery. One patient had Endo-SPONGE therapy abandoned and conversion to a permanent end colostomy after accidental intraperitoneal placement of the sponge.

CONCLUSIONS: Early use of Endo-SPONGE therapy appears to offer a minimally invasive and effective way of closing the presacral cavity after a pelvic anastomotic leak, reducing the risk of permanent stoma and resulting in acceptable bowel function. Endo-SPONGE-specific complications can occur.

Colorectal Dis. 2011 Nov;13 Suppl 7:18-22.

Early, minimally invasive closure of anastomotic leaks: a new concept.

Verlaan T¹, Bartels SA, van Berge Henegouwen MI, Tanis PJ, Fockens P, Bemelman WA.

Author information:

1 Department of Surgery, Academic Medical Center, University of Amsterdam, Amsterdam, the Netherlands.

Chronic pelvic sepsis after ileoanal or coloanal anastomosis precludes ileostomy closure and, even if closure is ultimately possible, function of the neorectum is badly affected. Early closure of the anastomotic leak might prevent chronic pelvic sepsis and its adverse sequelae. In our experience of early closure in a consecutive group of six patients with a leaking low anastomosis (five with ileoanal pouch anastomosis and one after a low anterior resection), we were able to achieve anastomotic closure in five by means of initial Endo-SPONGE therapy followed either by early suture (four patients) or endoscopic clip repair (one patient). Early minimally invasive closure of low anastomotic leaks is therefore possible provided that the para-anastomotic cavity is drained well prior to closure and the anastomosis is defunctioned.

Tech Coloproctol. 2010 Sep;14(3):279-81.

Endoluminal vacuum therapy for anastomotic leaks after rectal surgery.

Arezzo A¹, Miegge A, Garbarini A, Morino M.

Author information:

1 Digestive, Colorectal and Minimal Invasive Surgery, University of Turin, Turin, Italy. alberto.arezzo@unito.it

Anastomotic leakage after rectal surgery is a very serious complication and is the main cause of postoperative morbidity and mortality. We describe three cases of rectal leakage which we treated with endoscopic vacuum-assisted closure. We used the Endo-SPONGE (Aesculap AG, Germany), which consists of an open-cell, cylindrical polyurethane sponge connected to a drainage tube which is linked to a vacuum system to exert constant suction. The possible role of this new tool in the management of anastomotic leaks is also discussed.

World J Gastroenterol. 2010 Sep 28;16(36):4570-4.

Recurrent abscess after primary successful Endo-SPONGE treatment of anastomotic leakage following rectal surgery.

Riss S¹, Stift A, Kienbacher C, Dauser B, Haunold I, Kriwanek S, Radlsboek W, Bergmann M.

Author information:

1 Division of General Surgery, Department of Surgery, Medical University of Vienna, Währinger Gürtel 18-20, A-1090 Vienna, Austria. stefan.riss@meduniwien.ac.at

AIM: To assess long-term efficacy of initially successful Endo-SPONGE assisted therapy.

METHODS: Between 2006 and 2009, consecutive patients who had undergone primary successful Endo-SPONGE treatment of anastomotic leakage following rectal cancer surgery were enrolled in the study. Patients were recruited from 6 surgical departments in Vienna. Clinical and oncologic outcomes were assessed through routine endoscopic and radiologic follow-up examination.

RESULTS: Twenty patients (7 female, 13 male) were included. The indications for Endo-SPONGE treatment were anastomotic leakage (N = 17) and insufficiency of a rectal stump after Hartmann's procedure (N = 3). All patients were primarily operated for rectal cancer. The overall mortality rate was 25 %. The median follow-up duration was 17 mo (range 1.5-29.8 mo). Five patients (25 %) developed a recurrent abscess. Median time between last day of Endo-SPONGE therapy and occurrence of recurrent abscess was 255 d (range 21-733 d). One of these patients was treated by computed tomography-guided drainage and in 3 patients Hartmann's procedure had to be performed. Two patients (10 %) developed a local tumor recurrence and subsequently died.

CONCLUSION: Despite successful primary outcome, patients who receive Endo-SPONGE therapy should be closely monitored in the first 2 years, since recurrence might occur.

ABSTRACTS

Colorectal Dis. 2010 Jul;12(7 Online):e104-8.

Endo-SPONGE assisted treatment of anastomotic leakage following colorectal surgery.

Riss S¹, Stift A, Meier M, Haiden E, Grünberger T, Bergmann M.

Author information:

1 Department of Surgery, Medical University of Vienna, Vienna, Austria.

AIM: Endo-SPONGE assisted treatment (Endo-SPONGE) represents a novel approach to treat patients with anastomotic dehiscence following anterior resection for rectal cancer. Yet, limited data are available to predict success, compatibility with radiotherapy and/or chemotherapy as well as acceptance by the patients.

METHOD: Between September 2007 and June 2008, nine patients suffering from anastomotic leakage after anterior rectal resection (N = 6) or suffering from leakage of rectal stump following Hartmann's procedure (N = 3) were treated by Endo-SPONGE. We recorded clinical outcome and patient's comfort using a 10-point visual analogue scale (VAS).

RESULTS: Median time of Endo-SPONGE treatment was 3 weeks (range: 2-8). There were no minor or major complications. In 6 (66.6 %) patients, the anastomotic leakage healed successfully. Three patients showed no response and needed further surgical intervention. The lack of success was due to complexity of the leakages, which comprised either more than 270 degrees of the circumference or consisted of two distant fistulas. Formation of granulation tissue was unaffected by chemotherapy. For the question 'alteration in daily life activity', a median score of 5 (range: 1-9) was found. Measuring 'pain sensation' during Endo-SPONGE treatment patients scored a median of 3 (range: 0-6).

CONCLUSIONS: Endo-SPONGE treatment can be recommended as an alternative approach to treat pelvic sepsis following anastomotic dehiscence or rectal stump insufficiency. Extended leakages should be treated by different approaches having little probability of successful healing, but can lead to discomfort for the patient. Radiochemotherapy does not cause a problem for application of the Endo-SPONGE.

Surg Endosc. 2009 Jun;23(6):1379-83.

The Dutch multicenter experience of the Endo-SPONGE treatment for anastomotic leakage after colorectal surgery.

van Koperen PJ¹, van Berge Henegouwen MI, Rosman C, Bakker CM, Heres P, Slors JF, Bemelman WA.

Author information:

1 Department of Surgery, Academic Medical Center, P.O. Box 22660, 1100 A2, DD, Amsterdam, The Netherlands.
p.j.vankoperen@amc.uva.nl

BACKGROUND: Anastomotic leakage is a feared complication following colorectal surgery and is associated with early and long-term morbidity and mortality. The presacral cavity as the result of leakage can be treated with an Endo-SPONGE (Aesculap AG, Germany). The aim of this study was to assess the effectiveness of Endo-SPONGE treatment of the presacral cavity as the result of anastomotic leakage in the Netherlands.

METHODS: Between July 2006 and April 2008, 16 patients (M/F = 9:7) with median age 64 years (range 19-78 years) who underwent surgery for rectal cancer (N = 13) or ulcerative colitis (N = 3) were treated with the Endo-SPONGE treatment after anastomotic leakage.

RESULTS: Of the 16 patients, eight patients started with the Endo-SPONGE treatment within 6 weeks after the initial surgery. In these patients the Endo-SPONGE was placed after a median of 24 days (range 13-39 days) following surgery. In the remaining eight patients the Endo-SPONGE treatment was started later than 6 weeks after the initial surgery. In this group there was a median of 74 days (range 43-1,602 days) between surgery and the start of Endo-SPONGE placement. There was closure in six out of eight patients (75 %) in the group that started with the Endo-SPONGE treatment within 6 weeks of surgery compared with three out of eight patients (38 %) in the group that started later (p = 0.315). Closure was achieved in a median of 40 (range 28-90) days with a median number of 13 sponge replacements (range 8-17).

CONCLUSIONS: Endo-SPONGE placement can be helpful in the treatment for anastomotic leakage after colorectal surgery and might prevent a chronic presacral sinus. However, it is not yet clear if this new treatment modality results in quicker healing.

Surg Endosc. 2008 Aug;22(8):1818-25.

Endoscopic vacuum-assisted closure of anastomotic leakage following anterior resection of the rectum: a new method.

Weidenhagen R¹, Gruetzner KU, Wiecken T, Spelsberg F, Jauch KW.

Author information:

1 Department of Surgery, Klinikum Grosshadern, Ludwig-Maximilian-University of Munich, Marchioninstr, 15, D-81377, Munich, Germany. rolf.weidenhagen@med.uni-muenchen.de

BACKGROUND: Conservative treatment of anastomotic leakage after anterior resection of the rectum seems to be possible in patients who have no occurrence of generalized peritonitis. This report describes a new method of endoscopic management of large anastomotic leakage in these patients.

METHOD: The main feature of this new method is the endoscopically assisted placement of an open-cell sponge connected to a vacuum device into the abscess cavity via an introducer device. The sponge system is changed every 48-72 h.

RESULTS: Twenty-nine patients with an anastomotic leakage after anterior resection were treated with the endoscopic vacuum therapy. The total duration of endovac therapy was 34.4 +/- 19.4 days. The total number of endoscopic sessions per patient was 11.4 +/- 6.3. In 21 of the 29 patients, a protecting stoma was created at the primary operation. Four patients were treated successfully without the need of a secondary stoma. Definitive healing was achieved in 28 of the 29 patients.

CONCLUSIONS: Endoscopic vacuum-assisted closure is a new efficacious modality for treating anastomotic leakage following anterior resection due to an effective control of the septic focus. Further studies will show if it is possible to reduce the high mortality rate of patients with anastomotic leakage through the avoidance of surgical reinterventions while at the same time preserving the sphincter function.

ABSTRACTS

Colorectal Dis. 2008 Nov;10(9):943-4.

Endo-SPONGE treatment of anastomotic leakage after ileo-anal pouch anastomosis: report of two cases.

Van Koperen PJ¹, Van Berge Henegouwen MI, Slors JF, Bemelman WA.

Author information:

1 Department of Surgery, Academic Medical Center, Amsterdam, The Netherlands.

OBJECTIVE: The Endo-SPONGE was used in two patients in the treatment of anastomotic leakage following ileo-anal J-pouch reconstruction. Recently, local vacuum sponge treatment has shown to be effective to treat contained anastomotic leakage after low anterior anastomosis in rectal cancer patients.

METHOD: Two patients (male, 18 years; female, 40 years) who underwent restorative proctocolectomy for ulcerative colitis developed localized anastomotic leakage without general peritonitis. This was endoscopically managed by transanal placement of an Endo-SPONGE (Aesculap AG, Germany) after a diverting ileostomy was performed.

RESULTS: The sponge was frequently replaced until resolution of the sinus was achieved in 35 and 56 days.

CONCLUSION: Vacuum Endo-SPONGE treatment can help anastomotic leakage after ileo-anal pouch surgery.

Dis Colon Rectum. 2015;58:5 (e246).

Endo-SPONGE treatment of anastomotic leaks.

Milito G, Lisi G.

PURPOSE: Endoluminal vacuum therapy using Endo-SPONGE is a new endoscopic method to treat extraperitoneal anastomotic leakage following low anterior resections or Hartmann's stump leakage in the lesser pelvis, at an early stage and with no reintervention. This tool consists of an open-pored sponge inserted into the cavity. A drainage tube fixed to a low vacuum drainage system is then connected to the sponge through the anus. Thus, it is realized a continuous drainage of the secretion and the sponge cleans away the fibrin coatings, reduces in size and cleans the cavity.

METHODS: Between January 2003 and December 2013, 12 patients with anastomotic leakage following low anterior resection and neoadjuvant radiochemotherapy were treated with transrectal VAC. They were prospectively evaluated.

RESULTS: Stapled straight end to end colorectal anastomoses were performed in all patients between 3 and 7 cm above the anal verge, a protective loop ileostomy was performed in every patients. The diagnosis of anastomotic leakage was performed after a median interval of 15 days (range 7-22) the median size of the cavity was 81 x 46 mm. Fluid collection was drained, percutaneously in 10 cases, surgically in 2 patients who presented with a cavity of 80 x 55 mm and 85 x 50 respectively. The median duration of therapy was 35 days (range 16-51), with a 8-15 sponge exchanges for patient. Median healing time was 59 days (range 32-65). No intraoperative complications were recorded. We found 5 cases of mild anal pain successfully treated medically.

CONCLUSIONS: The Endo-SPONGE seems an effective minimally invasive procedure to treat extraperitoneal anastomotic leakage without reintervention reducing morbidity and mortality.

Support Care Cancer. 2014;22:1 SUPPL. 1 (S40).

Endo-SPONGE treatment of anastomotic leaks.

Milito G, Lisi G.

BACKGROUND AND AIMS: Endoluminal vacuum therapy using Endo-SPONGE is a new endoscopic method to treat extraperitoneal anastomotic leakage following low anterior resections or Hartmann's stump leakage in the lesser pelvis, at an early stage and with no reintervention. It is realized a continuous drainage of the secretion and the sponge cleans away the fibrin coatings, reduces in size and cleans the cavity.

METHODS: Between January 2005 and December 2013, 12 patients with anastomotic leakage following low anterior resection and neoadjuvant radiochemotherapy were treated with transrectal VAC. They were prospectively evaluated.

RESULTS: Stapled straight end to end colorectal anastomoses were performed in all patients between 3 and 7 cm above the anal verge, a protective ileostomy was performed in every patients. The diagnosis of anastomotic leakage was performed after a median interval of 15 days (range 7-22) the median size of the cavity was 81 x 46 mm. Fluid collection was drained, percutaneously in 10 cases, surgically in 2 patients who presented with a cavity of 80 x 55 mm and 85 x 50 respectively. The median duration of therapy was 35 days (range 16-51), with a 8-15 sponge exchanges for patient. Median healing time was 59 days (range 32-65). No intraoperative complications were recorded. 5 cases of mild anal pain successfully treated medically.

CONCLUSIONS: The Endo-SPONGE seems an effective minimally invasive procedure to treat extraperitoneal anastomotic leakage without reintervention reducing morbidity and mortality.

Colorectal Dis. 2013;15 SUPPL. 3 (90).

Our experience of using Endo-SPONGE treatment for anastomotic leakage after rectal surgery.

McAuley L, MacDonald L, Shalli K.

AIM: The aim of this study was to report the outcome of three patients who presented with a localised anastomotic leak following a laparoscopic anterior resection who were treated with an Endo-SPONGE.

METHOD: Between January 2011 and March 2013 three patients, complicated by a localised anastomotic leak following a laparoscopic low anterior resection were treated with Endo-SPONGE. We documented number of Endo-SPONGE changes required and endoscopic outcome of the cavity. Attention was paid to reduce cavity size to < 2 cm, therefore Endo-SPONGE was cut to size; the open end of the tube was sutured to retain maximum suction power.

RESULTS: One patient was successfully treated as an outpatient; the other two were kept as inpatients for social reasons. The average number of Endo-SPONGE changes was nine (7-12) with two patients achieving almost complete resolution of the cavity and one having a residual 2.5 cm cavity. All remained clinically well following cessation of treatment.

CONCLUSIONS: Endo-SPONGE was very effective in the management of localised pelvic sepsis following an anastomotic leak in one outpatient and two in patients with consistently good endoscopic outcomes. Optimum reduction of cavity's size will likely prevent recurrent sepsis following Endo-SPONGE treatment.

ABSTRACTS

Gut. 2013;62 SUPPL. 2 (A44).

Endoscopic transanal vacuum-assisted closure of low pelvic cavities following anastomotic and stump leakage.

Martel G, McElvanna K, McCallion K, McAllister I.

INTRODUCTION: Endoscopic transanal vacuum-assisted closure is a minimally invasive method used in the treatment of low pelvic anastomotic leaks and symptomatic cavities.

AIMS/BACKGROUND: We report our experience with this technique using Endo-SPONGE therapy in a series of 10 patients.

METHOD: All patients treated with Endo-SPONGE therapy between November 2008 and January 2013 in our hospital were identified. Data collected retrospectively from clinical and endoscopic notes included indication, duration of therapy, number of sponge changes, complications and outcome.

RESULTS: Ten patients (8 male, median age 59 years) underwent Endo-SPONGE therapy. Seven were treated for anastomotic leaks following low anterior resection. Two patients had symptomatic low pelvic cavities following ileal pouch excision and 1 was treated for a pelvic cavity following a perforated low Hartmann's stump. Seven patients were treated within 17 days (0-17 days) of diagnosis of pelvic sepsis. The remaining 3 patients were treated for chronic low pelvic cavities at intervals ranging from 5 months following index surgery. Median duration of treatment was 28.5 days (8-40 days) with a median number of sponge changes of 7 (2-11 changes). One patient developed a transient inflammatory response and pneumoperitoneum which settled with antibiotic therapy but there were no other complications. All patients had clinical resolution of pelvic sepsis and four patients had definitive cavity closure.

CONCLUSIONS: Endoscopic transanal vacuum-assisted closure is an effective low-risk method of controlling pelvic sepsis following anastomotic leak and can be used in the management of symptomatic cavities following pouch excision and low rectal stump leakage.

Support Care Cancer. 2013;21 SUPPL. 1 (S55-S56).

Endo-SPONGE treatment of anastomotic leaks.

Milito G, Cadeddu F.

BACKGROUND: Endoluminal vacuum therapy using Endo-SPONGE is a new endoscopic method to treat extraperitoneal anastomotic leakage following low anterior resections or Hartmann's stump leakage in the lesser pelvis, at an early stage and with no reintervention. This tool consists of an open-pored sponge inserted into the cavity. A drainage tube fixed to a low vacuum drainage system is then connected to the sponge through the anus. Thus, it is realized a continuous drainage of the secretion and the sponge cleans away the fibrin coatings, reduces in size and cleans the cavity.

METHODS: Between January 2003 and December 2012, 12 patients with anastomotic leakage following low anterior resection and neoadjuvant radiochemotherapy were treated with transrectal VAC. They were prospectively evaluated.

RESULTS: Stapled straight end to end colorectal anastomoses were performed in all patients between 3 and 7 cm above the anal verge, a protective loop ileostomy was performed in every patients. The diagnosis of anastomotic leakage was performed after a median interval of 15 days (range 7-22) the median size of the cavity was 81x46 mm. Fluid collection was drained, percutaneously in 10 cases, surgically in 2 patients who presented with a cavity of 80x55 mm and 85x50 respectively. The median duration of therapy was 35 days (range 16-51), with a 8-15 sponge exchanges for patient. Median healing time was 59 days (range 32-65). No intraoperative complications were recorded. We found 5 cases of mild anal pain successfully treated medically.

CONCLUSIONS: The Endo-SPONGE seems an effective minimally invasive procedure to treat extraperitoneal anastomotic leakage without reintervention reducing morbidity and mortality.

Eur Surg. 2013;45 SUPPL. 1 (8-9).

Endo-SPONGE treatment of anastomotic leaks.

Milito G, Cadeddu F.

BACKGROUND: Endoluminal vacuum therapy using Endo-SPONGE is a new endoscopic method to treat extraperitoneal anastomotic leakage following low anterior resections or Hartmann's stump leakage in the lesser pelvis, at an early stage and with no re-intervention. This tool consists of an open-pored sponge inserted into the cavity. A drainage tube fixed to a low vacuum drainage system is then connected to the sponge through the anus. Thus, it is realized a continuous drainage of the secretion and the sponge cleans away the fibrin coatings, reduces in size and cleans the cavity.

METHODS: Between January 2003 and December 2012, 12 patients with anastomotic leakage following low anterior resection and neoadjuvant radiochemotherapy were treated with transrectal vac. They were prospectively evaluated.

RESULTS: Stapled straight end to end colorectal anastomoses were performed in all patients between 3 and 7 cm above the anal verge, a protective loop ileostomy was performed in every patients. The diagnosis of anastomotic leakage was performed after a median interval of 15 days (range 7-22), median size of the cavity was 81 x 46 mm. Fluid collection was drained, percutaneously in 10 cases, surgically in 2 patients who presented with a cavity of 80 x 55 mm and 85 x 50 respectively. The median duration of therapy was 35 days (range 16-51), with a 8-15 sponge exchanges for patient. Median healing time was 59 days (range 32-65). No intraoperative complications were recorded. We found 5 cases of mild anal pain successfully treated medically.

CONCLUSIONS: The Endo-SPONGE seems an effective minimally invasive procedure to treat extraperitoneal anastomotic leakage without reintervention reducing morbidity and mortality.

Dig Liver Dis. 2013;45 SUPPL. 2 (S179-S180).

Endo-SPONGE for endoscopic management of anastomotic leakage after colorectal surgery: Results from a single centre experience.

Repici A, Pagano N, Ferrara E.C, Ciscato C, Strangio G, Vitetta E, Rando G, Elmore U, Fumagalli U, Rosati R, Spinelli A, Bona S, Montorsi M, Malesci A.

BACKGROUND AND AIM: Endo-SPONGE treatment represents a novel approach to manage patients with anastomotic dehiscence following colorectal surgery. Limited data are available to predict success rate and complication.

MATERIAL AND METHODS: Between September 2008 and October 2012 patients suffering from anastomotic leakage after surgery were managed with Endo-SPONGE placement. 18 pts underwent anterior rectal resection, all but one for rectal adenocarcinoma and one for rectal endometriotic nodule 3 pts underwent left hemicolectomy, for diverticulosis in one case and for left-sided adenocarcinoma in the other 2 cases; one patient underwent proctocolectomy for ulcerative colitis. After surgery, when anastomotic leakage was suspected, a CT scan was performed. The Endo-SPONGE is an open-pored polyurethane sponge which is installed transanally after examination and rinsing of the abscess cavity using a small-calibre gastroscope. Afterwards, the sponge is connected to a low vacuum suction bottle, creating a constant negative pressure. Primary outcome parameters were closure of the cavity and the ability to close the ileostomy.

RESULTS: In total 22 patients [M:F = 17:5 - mean age 67 years (range 37-89 y)] were included. Mean time of Endo-SPONGE treatment was 4.3 weeks (range: 1-32 weeks). There were 3 major complications: one case of ureteric fistula, one of ileal fistula and one of pararectal abscess. In 18 (82 %) patients, the anastomotic leakage healed successfully. Three patients showed no response (14 %) and one patient was improved for partial but not complete leakage healing at the time of data collection. The lack of success was associated with to complexity of the leakages, which comprised either more than 270 degrees of the circumference or consisted of two distant fistulas. Formation of granulation tissue and final

ABSTRACTS

healing were unaffected by concomitant radio or chemotherapy. Mean follow-up was 9 months. Three patients died during follow-up period because of disease progression in 2 cases and vascular accident in one. No mortality related to the Endo-SPONGE procedure was recorded.

CONCLUSIONS: According to the results of this largest ever published series, Endo-SPONGE treatment can be recommended as an alternative approach to treat pelvic sepsis following anastomotic dehiscence or rectal stump insufficiency. Extended leakages involving more than 2/3 of anastomosis are associated with failure of the treatment.

Dig Liver Dis. 2012;44 SUPPL. 2 (S139).

Long term efficacy of vacuum-assisted therapy (Endo-SPONGE) in anastomotic leakage following anterior rectal resection.

Buzzi A, Mussetto A, Tampieri I, Brancaccio M.L, Casetti T.

BACKGROUND AND AIM: Anastomotic leakage is a serious and frequent complication after anterior rectal resection ranging between 1-24 %. Recently, it has been described the application of local vacuum sponge treatment (Endo-SPONGE, Aesculap AG, Germany) of locally contained anastomotic leakage after anterior resection in rectal cancer patients. Treatment failure has been associated with delay in starting vacuum therapy after initial surgery. Recurrent abscess after primary successful Endo-SPONGE treatment has also been described. The aim of our study was to test the long-term efficacy of Endo-SPONGE therapy in a group of patient treated in our center with vacuum assisted therapy because of anastomotic leakage after colorectal surgery.

MATERIAL AND METHODS: 9 patients with a presacral cavity after an anastomotic leakage were treated using the vacuum therapy (Endo-SPONGE). All of them had a colo-rectal anastomosis according to Knight and Griffen following an anterior resection of the rectum for rectal cancer. The Endo-SPONGE was changed every 2-4 days to prevent the tissue from growing into the sponge causing painful sponge exchanges. A defunctioning ileostomy was present in all patients. Each patient had a follow-up colonoscopy and a lower GI series at least 2 months after complete closure of the abscess cavity.

RESULTS: 8 out 9 patients (89 %) showed closure of the anastomotic leakage after a mean of 15 sponge changes (9-23 changes). The ileostomy had been closed in all patients with a closed abscess cavity (8 pts). The only failure was not associated with delay between surgery and treatment (about 20 days after surgery in our patient). During the follow up period (mean 18.4 months, range 6-30) we observed one recurrence of a small presacral abscess after 8 months of follow-up that resolved with conservative treatment. Two patients died after 2 years and 1 year of follow-up because of metastatic rectal cancer and prostate cancer, respectively.

CONCLUSIONS: Endo-SPONGE placement can be helpful in the treatment of anastomotic leakage after colorectal surgery. Treatment failure was not associated with delay in starting treatment in our patient. We observed one case of recurrent abscess that healed with conservative treatment eight months after therapy was stopped.

Tech Coloproctol. 2012;16:1 (106).

Endoluminal vacuum therapy of anastomotic leakage following low anterior resection.

Milito G, Cadeddu F, Grande M, De Luca E, Ciangola C.I, Tucci G.

BACKGROUND: The most important surgical complication following rectal resection with anastomosis is symptomatic anastomotic leakage. The clinical leakage rate after anterior resection varies from 2.8 to 20 % and is associated with 6-22 % mortality rate. Endo-SPONGE is a minimally invasive method for treating anastomotic leaks that are endoscopically accessible in the low rectal area.

METHODS: We successfully treated 8 patients with an anastomotic leak following low anterior resection for rectal cancer with Endo-SPONGE. Endo-SPONGE consists of an open-pored sponge inserted into the cavity using a flexible endoscope. The sponge is then connected through a Y tube with a vacuum-assisted system (REDYROB Trans Plus bottle). Thus, there is continuous drainage of the secretions, and the sponge cleans away the fibrin coatings, reduces in size and cleans the cavity. The sponge system is changed every 48 h. The size of the new sponges applied during the treatment is reduced to fit the decreasing dimensions of the cavity. When the cavity is approximately 1 x 0.5 cm large, Endo-SPONGE treatment is ended.

RESULTS: In all 8 cases, Endo-SPONGE was successful, relieving patients from infectious symptoms. The treatment was performed on an outpatient basis. The mean duration of therapy was 27 days, with 8-15 sponge exchanges per patient. Mean healing time was 48 days. No intraoperative complications were recorded. We found 3 cases of mild anal pain successfully treated medically.

CONCLUSIONS: Endo-SPONGE seems an effective minimally invasive procedure for treating extraperitoneal anastomotic leakage without reintervention, thus reducing morbidity and mortality among patients.

ABSTRACTS

Tech Coloproctol. 2011;15:2 (230).

Endoluminal vacuum therapy of anastomotic leakage following low anterior resection.

Cadeddu F, Milito G.

BACKGROUND: The most important surgical complication following rectal resection with anastomosis is symptomatic anastomotic leakage. The clinical leakage rate after anterior resection varies from 2.8 to 20 % and is associated with a 6-22 % mortality rate and with a 10-100 % risk of permanent stoma. Endo-SPONGE (Aesculap AG, Germany) is a minimally invasive method to treat anastomotic leak endoscopically accessible in the low rectal area.

METHODS: We successfully treated 8 patients with an anastomotic leak following low anterior resection for rectal cancer with Endo-SPONGE. Endo-SPONGE consists in an open-pored sponge inserted into the cavity using a flexible endoscope. The sponge is precisely cut according to the size of leakage cavity and inserted in the cavity through a flexible endoscope using an over-tube for the endoscope and a pusher to place the device inside the cavity. The sponge is then connected through a Y-tube with a vacuum-assisted system (REDYROB Trans Plus bottle). Thus, it is realized a continuous drainage of the secretion and the sponge cleans away the fibrin coatings, reduces in size and cleans the cavity. The sponge system is changed every 48 h. The size of the new sponges applied during the treatment is reduced to fit the decreasing dimension of the cavity. When the cavity is approximately 1 x 0.5 cm large, the Endo-SPONGE treatment is ended.

RESULTS: In all 8 cases, Endo-SPONGE was successful, relieving patients from infectious symptoms; the treatment was performed on an outpatient basis. The mean duration of therapy was 27 days, with an 8-15 sponge exchanges for patient. Mean healing time was 48 days. No intraoperative complications were recorded. We found three cases of mild anal pain successfully treated medically.

CONCLUSIONS: Endo-SPONGE seems an effective minimally invasive procedure to treat extraperitoneal anastomotic leakage without reintervention reducing morbidity and mortality among patients.

Eur Surg. 2011;43 SUPPL. 240 (5-6).

Endoluminal vacuum therapy of anastomotic leakage following low anterior resection.

Cadeddu F, Milito G.

BACKGROUND: The most important surgical complication following rectal resection with anastomosis is symptomatic anastomotic leakage. The clinical leakage rate after anterior resection varies from 2.8-20 % and is associated with a 6-22 % mortality rate. Endo-SPONGE is a minimally invasive method to treat anastomotic leak endoscopically accessible in the low rectal area.

METHODS: We successfully treated 8 patients with an anastomotic leak following low anterior resection for rectal cancer with Endo-SPONGE. Endo-SPONGE consists in an open-pored sponge inserted into the cavity using a flexible endoscope. The sponge is then connected through an Y tube with a vacuum-assisted system (REDYROB Trans Plus bottle). Thus, it is realized a continuous drainage of the secretion and the sponge cleans away the fibrin coatings, reduces in size and cleans the cavity. The sponge system is changed every 48 hours. The size of the new sponges applied during the treatment is reduced to fit the decreasing dimension of the cavity. When the cavity is approximately 1 x 0.5 cm large the Endo-SPONGE treatment is ended.

RESULTS: In all 8 cases Endo-SPONGE was successful, relieving patients from infectious symptoms; the treatment was performed on an outpatient basis. The mean duration of therapy was 27 days, with an 8-15 sponge exchanges for patient. Mean healing time was 48 days. No intraoperative complications were recorded. We found three cases of mild anal pain successfully treated medically.

CONCLUSIONS: Endo-SPONGE seems an effective minimally invasive procedure to treat extraperitoneal anastomotic leakage without reintervention reducing morbidity and mortality among patients.

Tech Coloproctol. 2011;15:1 (113).

Treatment of anastomotic leakage following low anterior resection with Endo-SPONGE.

Cadeddu F, Selvaggio I, Milito G.

BACKGROUND: The most important surgical complication following rectal resection with anastomosis is symptomatic anastomotic leakage. The clinical leakage rate after anterior resection varies from 3 to 19 % and is associated with a 6-22 % mortality rate and a 10-100 % risk of permanent stoma. Endo-SPONGE (Aesculap AG, Germany) is a minimally invasive method of treating anastomotic leaks that are endoscopically accessible in the low rectal area. We present the video of a 70-year-old patient with an anastomotic leak following low anterior resection for rectal cancer successfully treated with Endo-SPONGE.

METHODS: Between January 2007 and December 2009, 5 patients with anastomotic leakage following low anterior resection were treated with transrectal VAC treatment at the University Hospital Tor Vergata, Rome and were prospectively evaluated. Endo-SPONGE consists of an open pore sponge inserted into the cavity using a flexible endoscope. The sponge is cut to fit the size of leakage cavity and inserted in the cavity through a flexible endoscope using an overtube for the endoscope and a pusher to push the sponge system forward and place it in the cavity. The sponge is then connected through a Y tube with a controllable drainage system (REDYROB Trans Plus bottle). Thus, it is realized a continuous drainage of the secretion, and the sponge cleans away the fibrin coatings, reduces in size and cleans the cavity. The sponge system is changed perennially every 48 h. The size of the new sponges applied during the treatment is reduced to fit the decreasing dimension of the cavity. When the cavity is approximately 1x0.5 cm large, the Endo-SPONGE treatment is ended.

RESULTS: The median age was 66 years (range 42-75 years). The diagnosis of anastomotic leakage was made after a median interval of 15 days (range 10-8 days) the median size of the cavity was 66x44 mm. In all patients, the fluid collection was drained, percutaneously in 4 patients and surgically in one patient who

presented with a cavity of 80x55 mm. In all 5 cases, Endo-SPONGE was successful, in relieving patients from symptoms of infection; the treatment was performed on an outpatient basis. The median duration of therapy was 25 days (range 16-35 days), with a 8-15 sponge exchanges per patient. Median healing time was 46 days (range 32-60 days). No intraoperative complications were recorded.

CONCLUSIONS: In summary, considering the European experience, the Endo-SPONGE seems an effective minimally invasive procedure for the treatment of extraperitoneal anastomotic leakage without reintervention reducing morbidity and mortality among patients. However, a prospective large randomized multicentric trial comparing Endo-SPONGE and conservative treatment taking into account morbidity and quality of life of patients is warranted.

ABSTRACTS

Tech Coloproctol. 2011;15:1 (113).

Endo-SPONGE treatment of a persisting presacral sinus after anastomotic leakage following laparoscopic total mesorectal excision.

Marino F, Simone M, Centonze A, Bottalico M.

Colorectal anastomotic leakage remains one of the most feared complications after total mesorectal excision (TME). Endoscopic vacuum-assisted closure with Endo-SPONGE (Aesculap AG, Germany) has been proposed as a conservative treatment in patients without occurrence of generalized peritonitis.

CASE REPORT: a 62-year-old man was admitted to our unit for a persisting presacral sinus after anastomotic leakage following TME for rectal cancer performed two years earlier. Despite ileostomy and the placement of a loose seton to drain the purulent cavity located in the presacral space, the sinus persisted. Thus, the patient underwent transanal insertion of Endo-SPONGE consisting of a polyurethane sponge connected with a vacuum system to stimulate the formation of granulation tissue and to obtain a constant drainage of the sinus. With the gradual reduction in the cavity, the Endo-SPONGE was reduced in size every 3-4 days when the Endo-SPONGE was exchanged. Fifteen endoscopic sessions were necessary to obtain the closure of the sinus.

IN CONCLUSION: Use of Endo-SPONGE treatment seems to be an effective method of avoiding surgical reinterventions for persisting presacral sinus after anastomotic leakage following TME.

Colorectal Dis. 2010;12 SUPPL. 1 (28-29).

Endoluminal vacuum therapy of anastomotic leakage following low anterior resection.

Milito G, Cadeddu F.

PURPOSE: The most important surgical complication following rectal resection with anastomosis is symptomatic anastomotic leakage. The clinical leakage rate after anterior resection varies from 2.8 to 20 % and is associated with a 6-22 % mortality rate and with a 10-100 % risk of permanent stoma. Endo-SPONGE (Aesculap AG, Germany) is a minimally invasive method to treat anastomotic leak endoscopically accessible in the low rectal area.

MATERIALS AND METHODS: We successfully treated five patients with an anastomotic leak following low anterior resection for rectal cancer with Endo-SPONGE. Endo-SPONGE consists in an open-pored sponge inserted into the cavity using a flexible endoscope. The sponge is precisely cut according to the size of leakage cavity and inserted in the cavity through a flexible endoscope using an over tube for the endoscope and a pusher to place the device inside the cavity. The sponge is then connected through an Y tube with a vacuum-assisted system (REDYROB Trans Plus bottle). Thus, it is realized a continuous drainage of the secretion and the sponge cleans away the fibrin coatings, reduces in size and cleans the cavity. The sponge system is changed every 48 h. The size of the new sponges applied during the treatment is reduced to fit the decreasing dimension of the cavity. When the cavity is approximately 1 x 0.5 cm large the Endo-SPONGE treatment is ended.

RESULTS: In all five cases Endo-SPONGE was successful, relieving patients from infectious symptoms; the treatment was performed on an outpatient basis. The mean duration of therapy was 25 days, with an 8-15 sponge exchanges for patient. Mean healing time was 46 days. No intraoperative complications were recorded. We found three cases of mild anal pain successfully treated medically.

CONCLUSIONS: Endo-SPONGE seems an effective minimally invasive procedure to treat extraperitoneal anastomotic leakage without reintervention reducing morbidity and mortality among patients.

Dig Liver Dis. 2010;42 SUPPL. 2 (S179).

Endoscopic vacuum-assisted treatment of anastomotic leakage following anterior resection of the rectum: Is it effective in real life.

Di Mitri R, Russo G, Mocciaro F, Carpino S, Gargano G, Marino A, Marchesa P.

BACKGROUND AND AIM: Anastomotic leakage following anterior resection of the rectum requires careful evaluation of risks and benefits in the management. A new endoscopic vacuum-assisted treatment of anastomotic leakage has been recently proposed with considerable success rate. Aim of this study is to report the experience of a referral tertiary centre.

MATERIAL AND METHODS: From Jan. 2009 to Oct. 2009 patients (pts) with diverting stoma, who underwent to rectal resection for rectal cancer and severe ulcerative colitis, were observed for post-surgical anastomotic leak. All these pts were treated with Endo-SPONGE (Aesculap AG, Germany). The placement was endoscopically assisted connecting the open-cell sponge to a vacuum device into the abscess cavity via an introducer device. The sponge system was changed every 48-72 h. The procedures took on average 15 minutes and were performed by an experienced endoscopists. Technical/clinical success, symptomatic recurrence and adverse events were recorded.

RESULTS: 5 male pts were enrolled for treatment with Endo-SPONGE. The mean age was 51.6 years (range 32-67); the deep of cavities ranged between 4 to 6 cm. One patient was operated for severe ulcerative colitis and 4 pts for colorectal cancer. All these 4 pts were previous submitted to chemo/radiotherapy. The 1st patient obtained a significant improvement after one session. The remainder 4 pts:

- 1) one was treated for 6 sessions (20 days) and stopped the treatment for arterial bleeding after Endo-SPONGE removal (the only adverse event observed);
- 2) the other 3 pts were treated for a mean of 6.3 sessions (range 6-15) and 30.3 days (range 20-50). All of these 3 pts achieved a significant improvement with cavity reduction ≤ 1 cm followed by elective closure of diverting stoma. The comfort of the pro-

cedure was judged good. Symptomatic and leak recurrence were observed in 2 pts after a mean of 5, 5 months from the closure of the stoma. These pts were operated on to resolve the leak recurrence.

CONCLUSIONS: Endoscopic vacuum-assisted closure may be proposed as a new efficacious modality for treating anastomotic leakage following anterior resection, although our results showed a significant efficacy in a low rate of pts. Maybe no cancer history and small size of cavity predict a better long-term outcome. Further RCTs are needed to confirm the role of Endo-SPONGE therapy for anastomotic leak in order to improve pts's outcomes and QoL.

ABSTRACTS

Tech Coloproctol. 2010;14:1 (78).

Endoscopic vacuum-assisted closure of chronic pelvic abscesses following anterior resection of the rectum.

Morino M, Arezzo A, Garbarini A.

BACKGROUND: Chronic abscesses after anastomotic leakage following anterior resection of the rectum create a challenging situation that requires careful evaluation of risks and benefits in management, as the possibility of a definitive abdomino-perineal amputation of the rectum is not remote. A new conservative treatment of acute anastomotic leakage after anterior resection of the rectum has been recently proposed with a considerable success rate. The aim of this report is to demonstrate the possibility of treatment of misdiagnosed chronic abscesses as well.

METHODS: Two patients, who underwent rectal resection 24 and 34 months respectively, prior to presentation at our clinic, both received chemo- and radio-therapy, and were recruited for our study because they were suffering from a chronic pelvic abscess located in front of the sacrum. One had a diverting stoma, while the other had already had stoma closure after primary surgery. Both underwent a novel treatment consisting of attempted endoscopic vacuum-assisted closure (Endo-SPONGE, Aesculap AG, Germany). The main feature of this new method is the endoscopically assisted placement of an open-cell sponge connected to a vacuum device into the abscess cavity via an introducer device. The fistula orifice is first cannulated, and then dilated by means of a 20 mm balloon. The endoscope is advanced into the cavity. The outer sheath of the introducer system is advanced under endoscopic control over the scope till the end of the cavity is reached. The endoscope is then removed leaving the outer sheath in place. The sponge is introduced into the distal end of the sheath. The sponge is pushed through the outer sheath by the inner sleeve and finally released in the cavity. The evacuation tube coming out of the anus of the patient is connected to a vacuum device. The sponge system is changed every 48-72 h, till the cavity is fully covered by a new epithelium and smaller than 10 mm in diameter.

RESULTS: The abscess of the first patient was completely healed in 45 days and 17 sessions. The second patient is still under treatment, but after 5 weeks and 12 sessions of treatment the abscess cavity is reduced to <50 % of its original size. The patient without a diverting stoma was given enteral nutrition for the first week, to avoid feces formation and transit. The comfort of the procedure was judged good by both patients. No signs of abdominal sepsis were noted during treatment.

CONCLUSIONS: Endoscopic vacuum-assisted closure may be proposed as a new, effective, modality for treating not only acute anastomotic leaks following anterior resection but also chronic and misdiagnosed pelvic abscesses. Further studies will demonstrate the real effectiveness and safety of the treatment.

REFERENCES

1. Paun BC, Cassie S, MacLean AR, Dixon E, Buie WD. Postoperative complications following surgery for rectal cancer. *Ann Surg*. 2010 May;251(5):807-18.
2. Blumetti J, Chaudhry V, Cintron JR, Park JJ, Marecik S, Harrison JL, Prasad LM, Abcarian H. Management of anastomotic leak: lessons learned from a large colon and rectal surgery training program. *World J Surg*. 2014 Apr;38(4):985-91.
3. Weidenhagen R, Gruetzner KU, Wiecken T, Spelsberg F, Jauch KW. Endoscopic vacuum-assisted closure of anastomotic leakage following anterior resection of the rectum: a new method. *Surg Endosc*. 2008 Aug;22(8):1818-25.
4. Kuehn F, Janisch F, Schwandner F, Alsfasser G, Schiffmann L, Gock M, Klar E. Endoscopic Vacuum Therapy in Colorectal Surgery. *J Gastrointest Surg*. 2016 Feb;20(2):328-34.
5. Keskin M, Bayram O, Bulut T, Balik E. Effectiveness of Endoluminal Vacuum-assisted Closure Therapy (Endosponge) for the Treatment of Pelvic Anastomotic Leakage After Colorectal Surgery. *Surg Laparosc Endosc Percutan Tech*. 2015 Dec;25(6):505-8.
6. Strangio G, Zullo A, Ferrara EC, Anderloni A, Carlino A, Jovani M, Ciscato C, Hassan C, Repici A. Endo-sponge therapy for management of anastomotic leakages after colorectal surgery: A case series and review of literature. *Dig Liver Dis*. 2015 Jun;47(6):465-9.
7. Gardenbroek TJ(1), Musters GD, Buskens CJ, Ponsioen CY, D'Haens GR, Dijkgraaf MG, Tanis PJ, Bemelman WA. Early reconstruction of the leaking ileal pouch-anal anastomosis: a novel solution to an old problem. *Colorectal Dis*. 2015 May;17(5):426-32.
8. Nerup N, Johansen JL, Alkhefagie GA, Maina P, Jensen KH. Promising results after endoscopic vacuum treatment of anastomotic leakage following resection of rectal cancer with ileostomy. *Dan Med J*. 2013 Apr;60(4):A4604.
9. Srinivasamurthy D, Wood C, Slater R, Garner J. An initial experience using transanal vacuum therapy in pelvic anastomotic leakage. *Tech Coloproctol*. 2013 Jun;17(3):275-81.
10. Riss S, Stift A, Kienbacher C, Dauser B, Haunold I, Kriwanek S, Radlsboek W, Bergmann M. Recurrent abscess after primary successful endo-sponge treatment of anastomotic leakage following rectal surgery. *World J Gastroenterol*. 2010 Sep 28;16(36):4570-4.

11. van Koperen PJ, van Berge Henegouwen MI, Rosman C, Bakker CM, Heres P, Slors JF, Bemelman WA. The Dutch multicenter experience of the endo-sponge treatment for anastomotic leakage after colorectal surgery. *Surg Endosc.* 2009 Jun;23(6):1379-83.
12. Verlaan T, Bartels SA, van Berge Henegouwen MI, Tanis PJ, Fockens P, Bemelman WA. Early, minimally invasive closure of anastomotic leaks: a new concept. *Colorectal Dis.* 2011 Nov;13 Suppl 7:18-22.
13. Arezzo A, Miegge A, Garbarini A, Morino M. Endoluminal vacuum therapy for anastomotic leaks after rectal surgery. *Tech Coloproctol.* 2010 Sep;14(3):279-81.
14. Riss S, Stift A, Meier M, Haiden E, Grünberger T, Bergmann M. Endo-sponge assisted treatment of anastomotic leakage following colorectal surgery. *Colorectal Dis.* 2010 Jul;12(7 Online):e104-8.
15. Richterich JP, Heigl A, Muff B, Luchsinger S, Gutzwiller JP. Endo-SPONGE—a new endoscopic treatment option in colonoscopy. *Gastrointest Endosc.* 2008 Nov;68(5):1019-22.
16. Van Koperen PJ(1), Van Berge Henegouwen MI, Slors JF, Bemelman WA. Endo-sponge treatment of anastomotic leakage after ileo-anal pouch anastomosis: report of two cases. *Colorectal Dis.* 2008 Nov;10(9):943-4.
17. Heeney A, Mulsow J, O'Connell PR. Vacuum-assisted closure of chronic anorectal fistula. *Int J Colorectal Dis.* 2010 Aug;25(8):1029-30.
18. Milito G, Lisi G. Endosponge treatment of anastomotic leaks. *Dis Colon Rectum.* 2015;58:5 (e246).
19. Milito G, Cadeddu F. Endosponge treatment of anastomotic leaks. *Eur Surg.* 2013;45 SUPPL. 1 (8-9).
20. McAuley L, MacDonald L, Shalli K. Our experience of using endo-sponge treatment for anastomotic leakage after rectal surgery. *Colorectal Dis.* 2013;15 SUPPL. 3 (90).
21. Repici A, Pagano N, Ferrara E.C, Ciscato C, Strangio G, Vitetta E, Rando G, Elmore U, Fumagalli U, Rosati R, Spinelli A, Bona S, Montorsi M, Malesci A. Endosponge for endoscopic management of anastomotic leakage after colorectal surgery: Results from a single centre experience. *Dig Liver Dis.* 2013;45 SUPPL. 2 (S179-S180).

REFERENCES

22. Martel G, McElvanna K, McCallion K, McAllister I. Endoscopic transanal vacuum-assisted closure of low pelvic cavities following anastomotic and stump leakage. *Gut*. 2013;62 SUPPL. 2 (A44).
23. Milito G, Cadeddu F, Grande M, De Luca E, Ciangola C.I, Tucci G. Endoluminal vacuum therapy of anastomotic leakage following low anterior resection. *Tech Coloproctol*. 2012;16:1 (106).
24. Buzzi A, Mussetto A, Tampieri I, Brancaccio M.L, Casetti T. Long term efficacy of vacuum-assisted therapy (Endo-sponge) in anastomotic leakage following anterior rectal resection. *Dig Liver Dis*. 2012;44 SUPPL. 2 (S139).
25. Cadeddu F, Selvaggio I, Milito G. Treatment of anastomotic leakage following low anterior resection with Endo-SPONGE. *Tech Coloproctol*. 2011;15:1 (113).
26. Cadeddu F, Milito G. Endoluminal vacuum therapy of anastomotic leakage following low anterior resection. *Tech Coloproctol*. 2011;15:2 (230).
27. Cadeddu F, Milito G. Endoluminal vacuum therapy of anastomotic leakage following low anterior resection. *Eur Surg*. 2011;43 SUPPL. 240 (5-6).
28. Marino F, Simone M, Centonze A, Bottalico M. Endo-SPONGE treatment of a persisting presacral sinus after anastomotic leakage following laparoscopic total mesorectal excision. *Tech Coloproctol*. 2011;15:1 (113).
29. Milito G, Cadeddu F. Endoluminal vacuum therapy of anastomotic leakage following low anterior resection. *Colorectal Dis*. 2010;12 SUPPL. 1 (28-29).
30. Morino M, Arezzo A, Garbarini A. Endoscopic vacuum-assisted closure of chronic pelvic abscesses following anterior resection of the rectum. *Tech Coloproctol*. 2010;14:1 (78).
31. Di Mitri R, Russo G, Mocciaro F, Carpino S, Gargano G, Marino A, Marchesa P. Endoscopic vacuum-assisted treatment of anastomotic leakage following anterior resection of the rectum: Is it effective in real life. *Dig Liver Dis*. 2010;42 SUPPL. 2 (S179).
32. Nagell CF, Holte K. Treatment of anastomotic leakage after rectal resection with transrectal vacuum-assisted drainage (VAC). A method for rapid control of pelvic sepsis and healing. *Int J Colorectal Dis*. 2006 Oct;21(7):657-60.

33. von Bernstorff W(1), Glitsch A, Schreiber A, Partecke LI, Heidecke CD. ETVARD (endoscopic transanal vacuum-assisted rectal drainage) leads to complete but delayed closure of extraperitoneal rectal anastomotic leakage cavities following neoadjuvant radiochemotherapy. *Int J Colorectal Dis.* 2009 Jul;24(7):819-25.
34. Bemelman WA(1). Vacuum assisted closure in coloproctology. *Tech Coloproctol.* 2009 Dec;13(4):261-3.
35. Borejsza-Wysocki M, Szmyt K, Bobkiewicz A, Malinger S, Świrkowicz J, Hermann J, Drews M, Banasiewicz T. Endoscopic vacuum-assisted closure system (E-VAC): case report and review of the literature. *Wideochir Inne Tech Maloinwazyjne.* 2015 Jul;10(2):299-310.

AESCULAP® – a B. Braun brand

Aesculap AG | Am Aesculap-Platz | 78532 Tuttlingen | Germany
Phone +49 7461 95-0 | Fax +49 7461 95-2600 | www.aesculap.com

The main product trademark "Aesculap" and the product trademark "Endo-SPONGE" are registered trademarks of Aesculap AG. "REDYROB" is a registered trademark of B. Braun Melsungen AG.

Subject to technical changes. All rights reserved. This brochure may only be used for the exclusive purpose of obtaining information about our products. Reproduction in any form partial or otherwise is not permitted.